

Transcranial Magnetic Stimulation

Applications in Neuropsychiatry

Mark S. George, MD; Sarah H. Lisanby, MD; Harold A. Sackeim, PhD

In the 1990s, it is difficult to open a newspaper or watch television and not find someone claiming that magnets promote healing. Rarely do these claims stem from double-blind, peer-reviewed studies, making it difficult to separate the wheat from the chaff. The current fads resemble those at the end of the last century, when many were falsely touting the benefits of direct electrical and weak magnetic stimulation. Yet in the midst of this popular interest in magnetic therapy, a new neuroscience field has developed that uses powerful magnetic fields to alter brain activity—transcranial magnetic stimulation. This review examines the basic principles underlying transcranial magnetic stimulation, and describes how it differs from electrical stimulation or other uses of magnets. Initial studies in this field are critically summarized, particularly as they pertain to the pathophysiology and treatment of neuropsychiatric disorders. Transcranial magnetic stimulation is a promising new research and, perhaps, therapeutic tool, but more work remains before it can be fully integrated in psychiatry's diagnostic and therapeutic armamentarium.

Arch Gen Psychiatry. 1999;56:300-311

Since the work of Penfield,¹ the possibility of noninvasive and focal stimulation of the brain has been an appealing vision that now seems to be realized. Transcranial magnetic stimulation (TMS) holds special promise as a tool to study localization of function, connectivity of brain regions, and pathophysiology of neuropsychiatric disorders. It may also have potential as a therapeutic intervention. For more than a century, it has been recognized that electricity and magnetism are interdependent. Passing current through a coil of wire generates a magnetic field perpendicular to the current flow in the coil. If a conducting medium, such as the brain, is adjacent to the magnetic field, current will be induced in the conducting me-

dium. The flow of the induced current will be parallel but opposite in direction to the

See also page 315

current in the coil. Thus, TMS has been referred to as “electrodeless” electrical stimulation, to emphasize that the magnetic field acts as the medium between electricity in the coil and induced electrical currents in the brain.

PROCEDURES

Transcranial magnetic stimulation involves placing an electromagnetic coil on the scalp (**Figure 1**). High-intensity current is rapidly turned on and off in the coil through the discharge of capacitors. This produces a time-varying magnetic field that lasts for about 100 to 200 microseconds. The magnetic field typically has a strength

From the Functional Neuroimaging Research Division, Departments of Radiology, Psychiatry, and Neurology, Medical University of South Carolina, Charleston (Dr George), Ralph H. Johnson Veterans Hospital, Charleston (Dr George), Department of Biological Psychiatry, New York State Psychiatric Institute, New York, (Drs Lisanby and Sackeim), and the Departments of Psychiatry (Drs Lisanby and Sackeim) and Radiology (Dr Sackeim), College of Physicians and Surgeons of Columbia University, New York, NY.

Dr George has research collaborations and grants from Dantec Medical (Medtronic), Copenhagen, Denmark, and Neotonus, Atlanta, Ga. Drs Sackeim and Lisanby have research grants from Magstim Co Ltd, Sheffield, England.

This article is also available on our Web site: www.ama-assn.org/psych.

of about 2 T (40 000 times the earth's magnetic field, or about the same intensity as the static magnetic field used in clinical magnetic resonance imaging). The proximity of the brain to the time-varying magnetic field results in current flow in neural tissue. The technological advances made in the last 15 years led to the development of magnetic stimulators that produce sufficient current in brain to result in neuronal depolarization.

Neuronal depolarization can also be produced by electrical stimulation, with electrodes placed on the scalp (referred to as transcranial electric stimulation). Electroconvulsive therapy (ECT) is an example of this. Importantly, unlike electrical stimulation, where the skull acts as a massive resistor, magnetic fields are not deflected or attenuated by intervening tissue. This means that TMS can be more focal than electric stimulation. Furthermore, for electrical stimulation to achieve sufficient current density in brain to result in neuronal depolarization, pain receptors in the scalp must be stimulated.^{2,3}

Transcranial magnetic stimulation is usually performed in outpatient settings, and, unlike ECT, does not require anesthesia or analgesics. Subjects usually notice no adverse effects except for occasional mild headache and discomfort at the site of the stimulation.

A striking effect of TMS occurs when one places the coil on the scalp over primary motor cortex. A single TMS pulse of sufficient intensity causes involuntary movement. The magnetic field intensity needed to produce motor movement varies considerably across individuals, and is known as the motor threshold.⁴ Placing the coil over different areas of the motor cortex causes contralateral movement in different distal muscles, corresponding to the well-known homunculus. Transcranial magnetic stimulation can be used to map the representation of body parts in the motor cortex on an individual basis.⁵ Subjectively, this stimulation feels much like a tendon reflex movement. Thus, a TMS pulse produces a powerful but brief magnetic field that passes through the skin, soft tissue, and skull, and

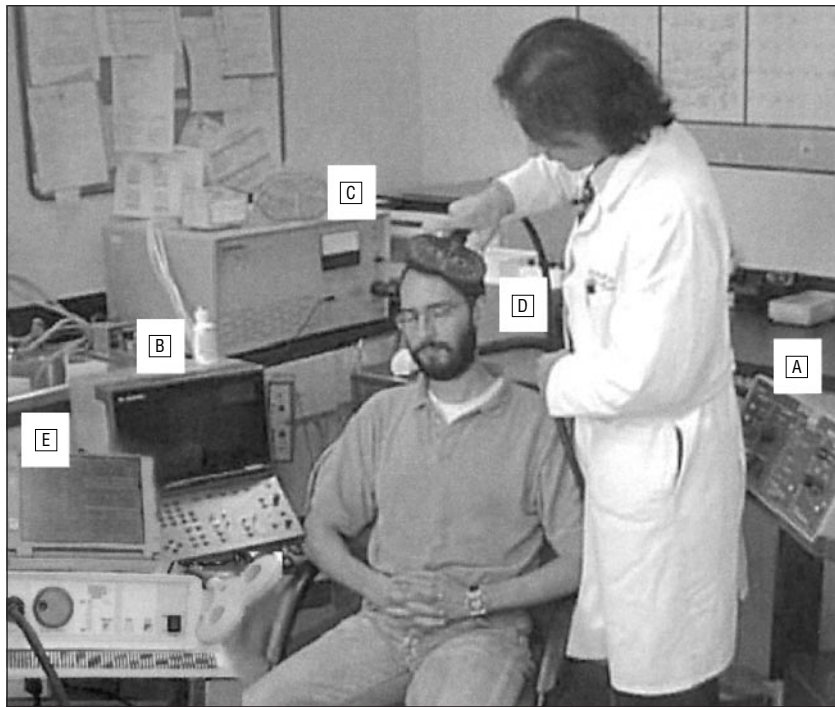


Figure 1. Example of transcranial magnetic stimulation (TMS) application. Ziad Nahas, MD, demonstrates a TMS figure-8 coil applied over the left prefrontal cortex of Ananda Shastri, PhD. Note that the subject is awake and alert, and is wearing earplugs for safety. The electromyography machine in the lower left corner (B) is used to determine the motor threshold for dosing of stimulation intensity. Several TMS devices and coils are pictured: A, Medtronic-Dantec (Copenhagen, Denmark); C, Cadwell (Kennewick, Wash) with water-cooled figure-8 coil; D, Neotonus (Atlanta, Ga); and E, Magstim (Sheffield, England).

induces electrical current in neurons, causing depolarization that then has behavioral effects (body movement). The TMS magnetic field declines logarithmically with distance from the coil. This limits the area of depolarization with current technology to a depth of about 2 cm below the brain's surface.⁶⁻⁸

CLINICAL AND BASIC APPLICATIONS IN NEUROPSYCHIATRY

Single TMS over motor cortex can produce simple movements. Over primary visual cortex, TMS can produce the perception of flashes of light or phosphenes.⁹ To date, these are the "positive" behavioral effects of TMS. Other immediate behavioral effects are generally disruptive. Interference with information processing and behavior is especially likely when TMS pulses are delivered rapidly and repetitively. Repeated rhythmic TMS is called repetitive TMS (rTMS). If the stimulation occurs faster than once per second (1 Hz) it is referred to as fast rTMS.¹⁰ During the study of thousands of subjects, no one has reported that TMS elicits memories,

or other complex psychological phenomena like those reported by Penfield et al¹¹ with direct intracranial electrical stimulation during neurosurgery. One explanation for this divergence is that the use of implanted electrodes in neurosurgery resulted in stimulation of deep cortex with high currents, perhaps causing spread away from the direct site. Furthermore, many of the phenomena that surgical patients experienced were part of their seizure aura. Similar TMS studies have not been performed in patients with epilepsy.

Most research on TMS has used magnetic field intensities near the motor threshold and, therefore, sufficient to cause neuronal depolarization. Research on TMS has also demonstrated that there are important physiological effects with lower intensities. For example, TMS at a low intensity can inhibit or enhance motor responses to closely following suprathreshold stimulation.¹² Nonetheless, a key distinction between TMS research and work on the behavioral effects of exposure to magnetic fields is that TMS effects occur at or near intensities sufficient to produce cortical neuron de-

polarization. The capacity to non-invasively excite or inhibit focal cortical areas represents a remarkable advance for neuroscience research. As an interventional probe in neuropsychiatric disorders, rTMS has the potential of taking functional imaging one step further by elucidating causal relationships.

POTENTIAL CLINICAL APPLICATIONS

Mood Disorders

The area of greatest public attention has been the use of TMS as an antidepressant. Several small open studies suggested that low-frequency TMS over the vertex might have antidepressant effects.¹³⁻¹⁵ Based on imaging findings of abnormal prefrontal function in depression^{16,17} and the evidence that modulation of prefrontal function is linked to the efficacy of ECT,¹⁸ George and Wassermann^{19,20} speculated that nonconvulsive stimulation over prefrontal cortex may produce a more

profound antidepressant effect than over the vertex. Prior to a treatment trial, they studied the immediate effects of right vs left dorsolateral prefrontal cortex (DLPFC) rTMS in medication-resistant depressed patients. In contrast to the direction of mood effects in normal volunteers, right DLPFC fast stimulation resulted in increased anxiety and worsened mood (M.S.G., unpublished observations, 1994).

Open daily left DLPFC rTMS was then given to 6 medication-resistant depressed inpatients. After 5 days of treatment, Hamilton Depression Rating Scale (HDRS) scores decreased by 26%²¹ (**Table**). In a later open trial, Figiel et al²² administered fast left prefrontal cortex rTMS to 56 largely medication-resistant depressed patients, referred for ECT. After 5 days of rTMS, they observed a 42% response rate (defined as >50% decrease in HDRS scores). Using a different open design, Conca et al²³ treated a cohort of depressed patients with a selective serotonin reuptake inhibitor

alone or with a selective serotonin reuptake inhibitor and rTMS augmentation. The rTMS group had a faster antidepressant response.

For any potential antidepressant treatment, double-blind, random assignment, placebo- or sham-controlled studies are critical. Designing blinded studies with TMS is a challenge. Someone knowledgeable about the patient's treatment condition must perform the TMS, and this person is in a position to influence outcome. Thus, none of the TMS studies have been truly double-blind.

Using a within-subject, crossover design, Pascual-Leone et al²⁴ reported a sham-controlled study. In TMS, holding the coil obliquely to the scalp mimics the sensations of "real" TMS, but produces minimal intracerebral current, thus serving as a sham. They found that fast left DLPFC rTMS for 5 days had marked antidepressant effects in psychotic depression, with 11 of 17 patients showing a decline in HDRS scores greater than 50%. Stimulation at

Summary of TMS Clinical Trials in Major Depression*

Investigators	Year Published	No. of Subjects	Design	Site	Intensity	Hz	Train Duration	Intertrain Interval	Trains per Session
Hoflich et al ¹³	1993	2	Open	Vertex	105%-130%	0.3	?	?	?
George et al ²¹	1995	6	Open	Left DLPFC	80%	20	2 s	60 s	20
Grisaru et al ¹⁴	1995	10	Open	Vertex	2 T	0.017	?	?	?
Kolbinger et al ¹⁵	1995	5	Open	Vertex	0.3 T above MT	0.25-0.5	?	?	?
	1995	5	Open	Vertex	0.3 T below MT	0.25-0.5	?	?	?
Conca et al ²³	1996	24	Open	Left DLPFC	1.9 T	<0.17	?	?	?
Pascual-Leone et al ²⁴	1996	17	Blind, crossover	Left DLPFC	90%	10	10 s	>50 s	20
George et al ³¹	1997	12	Blind, crossover	Left DLPFC	80%	20	2 s	>58 s	20
Epstein et al	1998	32	Open	Left DLPFC	110%	10	5 s	30 s	10
Figiel et al ²²	1998	56	Open	Left DLPFC	110%	10	5 s	30 s	10
Klein et al ³²	1998	14	Open	?	1 T, 0.1 ms	1	60 s	180 s	2
Grunhaus et al ²⁹	1998	16	Open	Left DLPFC	90%	10	2 s	?	20
Klein et al ³³	1999	71	Blind, parallel	Right DLPFC	1 T, 0.1 ms	1	60 s	180 s	2
Loo et al ²⁸	1998	18	Blind, parallel	Left DLPFC	110%	10	5 s	25 s	30
Nahas et al ³⁴	1998	10	Blind, parallel	Left DLPFC	100%	5	8 s	28 s	40
	1998	10	Blind, parallel	Left DLPFC	100%	20	2 s	22 s	40
	1998	10	Blind, parallel	Left DLPFC	Sham	20	2	28/22 s	40
Padberg et al ²⁷	1998	6	Blind, parallel	Left DLPFC	90%	10	5 s	?	5
	1998	6	Blind, parallel	Left DLPFC	90%	0.3	7 s	?	10
	1998	6	Blind, parallel	Left DLPFC	Sham	?	?	?	?

*TMS indicates transcranial magnetic stimulation; HDRS, Hamilton Depression Rating Scale; MT, motor threshold; rTMS, repetitive TMS; DLPFC, dorsolateral prefrontal cortex; and question mark, unknown.

other sites (right DLPFC, vertex) and sham had no antidepressant effects. This remarkable result was superior to what could be expected with any medication regimen, or even ECT.^{25,26} However, patients were not medication free and the study used a multiple crossover design (all subjects were enrolled for 5 months and received 5 types of stimulation, each for 5 consecutive days per month). Three follow-up studies have not observed the same magnitude or speed of response.²⁷⁻²⁹ Indeed, some studies have suggested that psychotic depression is resistant to rTMS in its current form.^{29,30}

George et al³¹ completed a double-blind, sham-controlled, single-crossover study of fast left DLPFC rTMS in 12 medication-resistant depressed outpatients using a weak intensity (80% of motor threshold). The improvement with 10 days of active rTMS was modest (average 26% decline in HDRS scores at 2 weeks), but significantly greater than with sham treatment. This

study also suffered from use of a crossover design in which carryover effects could not be ruled out, and some patients received maintenance medication.

An important question is whether the antidepressant effects of rTMS are region or frequency-dependent. Klein and colleagues^{32,33} randomized 71 depressed outpatients to 2 weeks of active or sham slow rTMS over *right* prefrontal cortex using a round, nonfocal coil. In the active group, 41% of TMS-treated patients responded with at least a 50% decrease in HDRS scores, and only 17% of the sham-treated patients met response criteria. This study challenged the specificity of antidepressant effects with left prefrontal stimulation. Importantly, slow rTMS has considerably less seizure risk than fast rTMS. A recent parallel-design, blinded study from Nahas et al³⁴ and George et al³⁵ suggests that slow (5 Hz) left prefrontal TMS may be as effective as fast (20 Hz) left stimulation. At 2 weeks, 6 of 10 subjects with slow rTMS, 3 of 10 sub-

jects with fast rTMS, and 0 of 10 subjects with sham TMS were "responders" (>50% decrease in HDRS scores). Similarly, Padberg et al²⁷ studied 18 nonpsychotic depressed patients with sham treatment, slow rTMS, or fast rTMS, all over the left prefrontal cortex. During 5 days, 5 of 6 in the slow group and 3 of 6 in the fast group improved (20%-30% decrease in HDRS scores), with no change in the sham group. In summary, further work using balanced designs is needed to determine whether the antidepressant effects of rTMS are region-, frequency-, or intensity-dependent.

How does TMS compare with ECT, and do the 2 modalities work through similar or differing mechanisms? Using a parallel-group, nonblinded design, Grunhaus et al²⁹ randomly assigned 40 inpatients to treatment with fast left DLPFC rTMS or ECT. Among nonpsychotic patients, up to 4 weeks of daily rTMS was equivalent in efficacy to ECT, but ECT showed a superiority among psychotically depressed patients. Pridmore et al³⁰ studied 22 outpatients with either left unilateral ECT for 2 weeks, or 1 ECT treatment per week followed by 4 days of left prefrontal rTMS. At the end of 2 weeks, the 2 arms were equally effective, with an average 75% decrease in HDRS scores. Unfortunately this study did not have a control arm of 1 day of ECT and sham TMS, to formally test the role of rTMS. However, it seems that TMS may not interfere with ECT mechanisms, and may be complementary.

As might be expected with a new technology, not all the initial rTMS trials have been positive. Loo et al²⁸ completed a parallel-group study with 18 nonpsychotic depressed patients randomized to fast left DLPFC or sham rTMS, with a 2-week treatment period. Despite using the same stimulation parameters as Pascual-Leone et al,²⁴ no difference was detected between active and sham treatment.

In the first study of acute mania, Belmaker and Grisaru³⁶ and Grisaru et al³⁷ randomized 17 patients to fast left or right prefrontal rTMS, in addition to standard pharmacological care. During the 2-week study period, the right prefrontal group had a greater decline

No. of Sessions	Total No. of Pulses	Improvement (% Decrease in HDRS Scores)	Comments
10	2500	?	No therapeutic effect
≥5	>2000	26	HDRS score decreased from 23.8 to 17.5
1	60	?	4 slight improvement, 1 worse, 5 no change
5	1250	15	
5	1250	34	
10	400	59	rTMS used as an add-on to medication
5	10 000	45	HDRS score decreased from 25.2 to 13.8 after 5 sessions
10	8000	17	rTMS superior to sham, but small decrease in depression rating
5	2500	52	Age <65 y, 4 dropouts, rTMS resulted in HDRS scores <10 in 50% of sample
5	2500	?	
10	1200	31	
20	8000	?	Comparison with ECT: 7/16 responded to rTMS, 12/18 to ECT
10	1200	50	HDRS scores dropped from 26 to 13; with sham treatment, from 26 to 20
20	15 000	23	rTMS caused significant decreases in HDRS scores after 10 sessions; however, no different from sham
10	16 000	44	6/10 responders at 2 wk
10	16 000	28	3/10 responders at 2 wk
10	16 000	24	0/10 responders
5	1250	?	3/6 responders
5	1250	?	5/6 responders
?	?	?	0/6 responders

in manic symptoms, raising the possibility that the laterality of fast rTMS necessary for antimanic effects is opposite to that needed for antidepressant effects.

These initial studies suggest that prefrontal TMS can exert short-term antidepressant or antimanic effects. On the optimistic side, they raise the specter that focal modulation of cortical excitability has therapeutic properties in mood disorders and that TMS may prove informative about the anatomy and physiology of the neural systems involved in achieving therapeutic effects. At the clinical level, TMS may ultimately offer an alternative to ECT for severe or treatment-resistant depression, particularly since the adverse effect profile of TMS is relatively benign. Repetitive TMS does not involve anesthesia administration or seizure induction and has no obvious cognitive sequelae (J. T. Little, unpublished data). Given the substantial delay in symptomatic improvement seen with traditional antidepressant medications,^{38,39} another potential use of TMS may be as an augmentation agent to hasten clinical response in pharmacologically treated patients.

However, routine clinical use of TMS in mood disorders is far from certain. None of the initial studies was truly double-blind, none of the key effects has been rigorously replicated, and the positive findings are based on small samples in short (1- to 2-week) trials. There are major discrepancies among the initial studies in the magnitude and nature of antidepressant effects. In addition to the usual concerns about sample comparability and the reliability of assessment,^{40,41} the therapeutic application of rTMS has particular methodological issues involving sham application⁴² and the parameters used. To complicate matters, unlike the motor cortex where the stimulus parameters can be titrated to a behavioral outcome, such as a motor evoked potential amplitude or observed movement, the prefrontal cortex is "silent." There is no evidence that it is appropriate to determine parameters for stimulation over prefrontal cortex based on effects of stimulation over the motor cortex. Combined TMS and imaging stud-

ies may help narrow the parameter selection for clinical trials in mood disorders.

Negative results should be expected given the limited basic knowledge behind the rTMS variables used in clinical trials. In this respect, it may be useful to note that the problem of multiple parameters also characterizes ECT. It was only after approximately 5 decades of clinical use that it was demonstrated that the anatomical site of electrical stimulation and the electrical dosage administered fundamentally influence the efficacy of ECT in major depression.^{43,44}

Transcranial magnetic stimulation carries the vision of tailoring the site and nature of stimulation to individual needs. It is uncertain whether this vision will be realized and whether a treatment role for rTMS will emerge. At the practical level, rTMS research is not supported with the resources devoted to pharmaceutical development. Given the large parameter space, it is difficult to see how rTMS treatment applications can be optimized without considerable basic research extending from cell culture preparations through whole animal models, including humans.

Anxiety Disorders

In a randomized trial of left and right prefrontal and midoccipital stimulation in 12 patients with obsessive-compulsive disorder, Greenberg et al⁴⁵ found that a single session of right prefrontal rTMS decreased compulsive urges for 8 hours. Mood was also transiently improved, but there was no effect on anxiety or obsessions. Using TMS probes, the same group reported decreased intracortical inhibition in patients with obsessive-compulsive disorder,^{46,47} which also has also been noted in patients with Tourette syndrome.^{48,49} McCann et al⁵⁰ reported that the condition of 2 patients with posttraumatic stress disorder improved during open treatment with 1-Hz rTMS over the right frontal cortex. Grisaru et al⁵¹ similarly stimulated 10 patients with posttraumatic stress disorder over motor cortex and found decreased anxiety.⁵¹ These preliminary findings await replication in controlled trials.

Schizophrenia

Somewhat surprisingly, TMS has been rarely used to study schizophrenia, with 1 report of an open clinical series of slow rTMS resulting in reduced anxiety.⁴³ There have been studies reporting slowed motor conduction time,⁵² and 3 cases of reduced auditory hallucinations following slow rTMS over the left temporal cortex.⁵³ In 8 patients with prominent negative symptoms, Nahas and colleagues⁵⁴ found that compared with sham stimulation, one 20-minute session of fast rTMS to the left DLPFC was associated with slightly improved negative symptoms, and also resulted in improved scores on an attentional task.

Movement Disorders

Therapeutic applications of TMS in movement disorders are preliminary. Fast rTMS of the motor cortex has been reported to improve performance on several motor measures in Parkinson disease,^{55,56} although this effect was recently not replicated.^{57,58} Slow rTMS has been reported to improve dystonia.⁵⁹ Even when seen, the beneficial effects in movement disorders have been short-lasting and thus without clinical application.

Epilepsy

The TMS motor threshold is reduced in patients with untreated epilepsy,⁶⁰ hinting at widespread problems in cortical excitability. Repetitive TMS has also been used presurgically to induce speech arrest for language localization.⁶¹ Therapeutically, there is 1 report of potential beneficial effects of slow rTMS in action myoclonus.⁶²

BASIC RESEARCH

As a noninvasive probe, TMS has the unique ability to map brain function, measure cortical excitability, and to modulate functional networks and examine their interrelations.

Motor and Sensory Function

Transcranial magnetic stimulation over the primary motor cortex

evokes movement in the contralateral limb and has provided information on the anatomical organization and functional characteristics of the motor system. Single-pulse TMS has been useful in precise mapping of motor cortex representations, and in demonstrating how these representations are altered in disease processes^{5,63-66} and models of disease processes, such as ischemic nerve block.⁶⁷ Cohen et al⁶⁴ found motor maps to be altered by conditions such as congenital mirror movements, amputations, spinal cord injury, and hemispherectomy. While TMS to the motor cortex readily evokes movement, TMS rarely elicits positive sensory phenomena.^{9,68} Nonetheless, TMS to the primary sensory cortex can block the perception of sensory stimulation.⁶⁶

Visual Information Processing

Several groups have applied single-pulse TMS or rTMS to the study of visual processing. Pascual-Leone et al⁶⁹ found that rTMS over the occipital lobe impaired detection of visual stimuli and rTMS over the parietal lobe induced selective extinction of contralateral visual stimuli during double-simultaneous presentation. Others have demonstrated inhibition of stereoscopic perception with occipital rTMS.⁷⁰ Work with single-pulse TMS has yielded even more precise localization and timing data. For example, motion discrimination has been disrupted with TMS to area V5.⁷¹⁻⁷³ Precise timing of the interval between visual presentation and TMS has permitted the study of the neuroanatomical basis of visual masking and backward masking phenomena.^{9,74,75}

Language

Repetitive TMS delivered to discrete areas in the language-dominant hemisphere can disrupt speech.^{61,76} This method has high concordance with established methods of speech lateralization, such as intracarotid sodium amytal infusion (Wada test),⁷⁷ although rTMS sometimes produces speech arrest in the cortex unconfirmed by the Wada test. This has limited its use as a pre-surgical mapping tool.

Memory

Studies of the memory effects of TMS and rTMS have been conflicting. A few reports found no short-term memory effects.^{78,79} However, other work demonstrated that rTMS over the left temporal and bilateral DLPFC can impair short-term verbal recall⁸⁰ and that rTMS over the DLPFC may disrupt short-term motor memory.⁸¹ Memory effects seem to depend on the choice of study paradigm, stimulation site, and parameters.

Emotion

There is evidence that rTMS can modulate mood systems in normal volunteers. Three studies found that rTMS over the left DLPFC transiently induced a mild increase in self-rated sadness, whereas right DLPFC rTMS produced a mild increase in self-rated happiness⁸²⁻⁸⁴ as early as 20 minutes⁸⁴ or as late as 5 to 8 hours poststimulation.⁸² As described, the mood effects of rTMS in patients with major depression may have an opposite laterality to those seen in normal volunteers. There has yet to be an investigation using TMS to probe the anatomy subserving the perception or expression of emotion.⁸⁵⁻⁸⁷

Cortical Excitability

In addition to mapping cortical representations, TMS can examine functional alterations in cortex.^{5,64-66} Such work has yielded valuable information about neurophysiological changes in a variety of clinical conditions.

Motor Threshold With Single-Pulse TMS

Motor threshold, the minimum magnetic intensity required to elicit a motor evoked potential in a target muscle, is increased in conditions of slowed conduction, like multiple sclerosis.⁸⁸ In contrast, motor threshold is decreased in untreated epilepsy, and this reverses with anti-convulsant treatment.^{60,89,90} Plasma levels of an anti-convulsant medication have been found to covary with motor threshold.⁹⁰ Transcranial magnetic stimulation measures of cor-

tical excitability have also been studied in major depression, without clear-cut results.^{91,92}

Conduction Latency With Single-Pulse TMS

The latency of motor responses evoked by TMS conveys information about conduction velocity. The difference in latency for responses evoked with cortical and cervical spinal TMS assesses the central motor conduction time. Central motor conduction time has been found to be abnormal in 72% of patients with multiple sclerosis,⁹³ and has been found to be delayed in other disorders associated with white matter hypomyelination⁹⁴ and in medication-free patients with schizophrenia.⁵²

Intracortical Inhibition and Facilitation With Paired-Pulse TMS

The motor evoked potential response to a TMS pulse preceded by a subthreshold conditioning pulse is reduced when the interstimulus interval is 1 to 4 milliseconds and enhanced when the interstimulus interval is 5 to 30 milliseconds,¹² reflecting intracortical inhibition and facilitation, respectively. Stimulation of one hemisphere can inhibit or facilitate responses elicited in the opposite hemisphere, indicating inter-hemispheric modulatory effects.⁹⁵ Paired-pulse inhibition is reduced in focal epilepsy⁹⁶ and enhanced by γ -aminobutyric acid (GABA)-ergic agents.⁶⁷ Pharmacological manipulations suggest that intracortical paired-pulse inhibition reflects the activation of inhibitory GABA-ergic and dopaminergic interneurons,¹² while paired-pulse facilitation reflects excitatory *N*-methyl-D-aspartate-mediated interneurons,⁶⁷ and motor threshold is modulated by ion channel conductivity.⁶⁷ These profiles provide novel methods to investigate local alterations in neurochemical systems.

Frequency-Dependent Effects on Cortical Excitability With rTMS

Some preliminary studies suggest that rTMS effects on cortical excit-

ability may depend on the frequency of stimulation. Manipulations of frequency and intensity may produce distinct patterns of facilitation (fast rTMS) and inhibition (slow rTMS) of motor responses with distinct time courses.^{97,98} These effects may last beyond the duration of the rTMS trains^{99,100} with enduring effects on spontaneous neuronal firing rates.¹⁰¹ Determining whether in fact lasting increases and decreases in cortical excitability can be produced as a function of rTMS parameters, and whether such effects can be obtained in areas outside of the motor cortex, are of key importance.

MECHANISMS OF TMS

To use TMS optimally, it is important to know how TMS is acting in the brain. Does TMS mimic normal brain physiology, or is it supraphysiologically depolarizing and activating different cell groups (excitatory, inhibitory, local, or remote) in a large region? Understanding of TMS mechanisms is being advanced through studies in animal models and by combining TMS with functional neuroimaging.

Animal Models

Transcranial magnetic stimulation studies with intracranial electrodes in rhesus monkeys have provided information about the nature and spatial extent of the rTMS-induced electric field.^{44,102} Corticospinal tract development, aspects of motor control, and medication effects on corticospinal excitability have been studied fairly extensively in nonhuman primates using single-pulse TMS.¹⁰³⁻¹¹¹ Such work has yielded information about TMS neurophysiological effects, such as the observation that TMS-evoked motor responses result from direct excitation of corticospinal neurons at or close to the axon hillock.¹¹¹

Animal rTMS studies have reported antidepressantlike behavioral and neurochemical effects. In particular, rTMS enhances apomorphine-induced stereotypy and reduces immobility in the Porsolt swim test.^{112,113} Repetitive TMS has been reported to induce ECT-like

changes in rat brain monoamines, β -adrenergic receptor binding, and gene induction.¹¹²⁻¹¹⁵ The effects of rTMS on seizure threshold are variable and may depend on the parameters and chronicity of stimulation.^{101,116} Repetitive TMS has been reported to have anticonvulsant activity in rodents similar to the anticonvulsant activity of ECT.¹¹² While encouraging regarding potential antidepressant effects of TMS, this work has been conducted in rodents, making extrapolation to human TMS difficult.

Combining TMS With Functional and Structural Neuroimaging

Neuroimaging studies have shown that TMS is biologically active, both locally in tissue under the coil and at remote sites, presumably through transsynaptic connections. Several studies have shown that the different parameters used in rTMS (location, intensity, frequency) affect the extent and type of neurophysiological alterations. Thus, there is considerable promise that functional imaging research will help elucidate basic TMS effects and the roles that different TMS parameters exert in modulating these effects. Theoretically, this may advance clinical research, particularly if combinations of location, intensity, and frequency are found to have divergent effects on neuronal activity. Transcranial magnetic stimulation imaging studies can be divided into 2 main categories: (1) using imaging to guide TMS coil placement and understand the spatial distribution of TMS magnetic fields in the brain, and (2) using imaging to measure TMS effects on neuronal activity.

Commonly, the positioning of the TMS coil on the scalp has been determined physiologically. Single TMS pulses are used to locate the optimal site for finger movement, and then coil placement over other regions is determined relative to this optimal site. The TMS-determined external location for thumb movement compares favorably with motor cortex thumb representation as determined in imaging studies.^{117,118}

However, in most clinical trials in depression, the coil was positioned at the DLPFC, by measuring

5 cm anterior to the optimal site for thumb movement.^{21,24,31,82-84} The primary motor area for the thumb varies across individuals, and a brain region referenced to this site will be even more varied in location given different head size and cortical morphology. Several groups have now begun using magnetic resonance imaging (MRI)-guided systems to determine the coil position over specific brain gyri guided either by a probabilistic brain^{119,120} or the subject's brain. Whether this affects TMS results is unclear.

Bohning et al⁶ demonstrated that an MRI scanner can be used to display the TMS magnetic field (producing a phase map; **Figure 2**). This work confirmed that the TMS field is not altered appreciably by head geometry. Further, by combining several TMS coils with different relative orientations, this technique can measure in 3 dimensions the capacity to focus and combine magnetic fields. Ultimately, TMS coil arrays combined with MRI may target deep brain structures.

Interleaving TMS and functional brain imaging offers much promise; however, technical issues have hampered initial research. It is sometimes difficult to match the imaging technique to the temporal duration of TMS. Owing to seizure risk at moderate intensity, fast rTMS can only be given in short pulse trains (1-8 seconds) with relatively long intervals between trains (20 seconds). With 18-fluorodeoxyglucose positron emission tomography to measure cerebral metabolism and water tagged with radioactive oxygen (¹⁵O) positron emission tomography to measure cerebral blood flow, physiological activity is integrated over periods of approximately 45 minutes and 1 minute, respectively. Therefore, the options have been to use slow rTMS and stimulate throughout the period of measurement or to have the measurements encompass substantial periods of rest between fast rTMS trains. Additional problems have concerned the interference produced by TMS with image acquisition. Thus, combined TMS and imaging studies were first done with radiotracers that could be injected outside the camera (positron emis-

sion tomography done with fluoro-deoxyglucose^{21,121,122} and perfusion single-photon emission computed tomography¹²³⁻¹²⁵). More recent work has interleaved TMS with positron emission tomography^{119,120,126} or blood oxygen level-dependent functional MRI.¹²⁷⁻¹²⁹

A major hypothesis in the TMS field has been that fast rTMS results in excitatory physiological changes, while slow rTMS has inhibitory effects. To date, imaging studies have yielded inconsistent results regarding this proposition. In fact, some slow rTMS imaging studies over motor¹²¹ or prefrontal cortex¹²² (**Figure 3**) have found decreased local and remote brain activity, while others have found increases.^{126,129} Some imaging studies of fast rTMS have found increased perfusion,¹¹⁹ but not all.^{30,120,123} Recently, with the interleaved TMS and functional MRI technique, researchers compared slow TMS-induced finger movement with voluntary movements that mimicked TMS. They found that the changes accompanying slow rTMS were much like those produced by voluntary movement.¹³⁰ Ultimately, TMS combined with functional MRI may allow for precise positioning and focusing of the TMS coil, with exact information obtained on the magnetic field produced, as well as the TMS-induced brain alterations in physiology and biochemistry. This area is advancing rapidly.

SAFETY

The safety issues involving TMS can be divided into immediate, short-term (hours to days following TMS), and long-term (weeks to months).¹⁰

Transcranial magnetic stimulation is not pleasant, and stimulation at higher intensities and frequencies is generally more painful. The pain experienced during rTMS is likely related to the repetitive stimulation of peripheral facial and scalp muscles, resulting in muscle tension headaches in a proportion of subjects (approximately 5%-20% depending on the study). These headaches respond to treatment with acetaminophen or aspirin. Magnetic stimulation also produces a

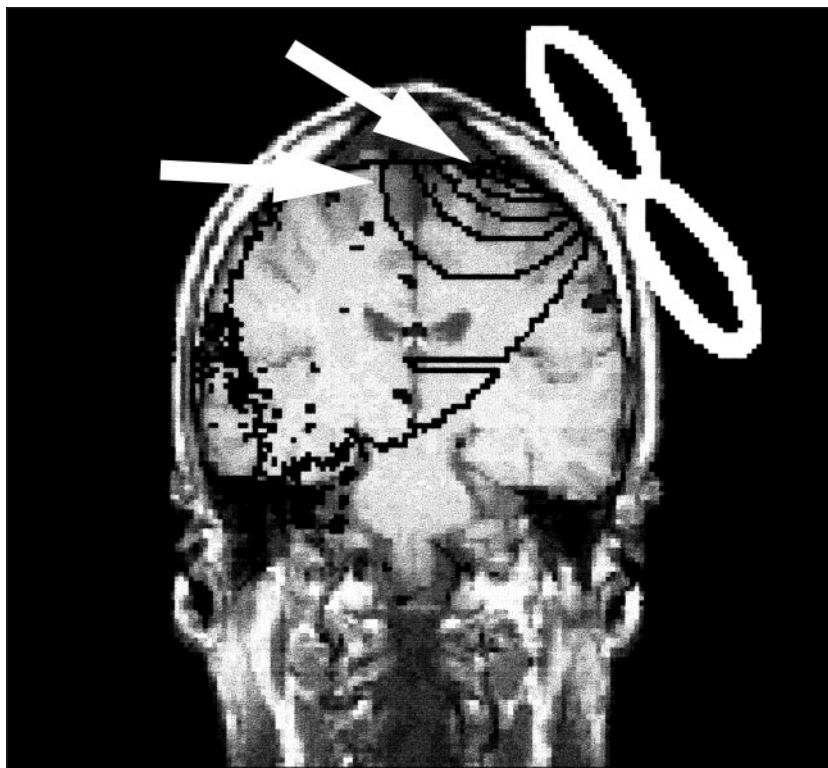


Figure 2. Structural imaging may guide transcranial magnetic stimulation (TMS) placement. A coronal magnetic resonance image of a subject where the location of the TMS coil is indicated above the left hemisphere motor area. The magnetic field produced by the TMS coil when it discharges is shown in black gauss lines drawn on the brain. Combining TMS with structural imaging may allow for exact guidance of TMS coils, as well as understanding where the TMS magnetic fields are distributed in the brain. (Image courtesy of Daryl Bohning, PhD, and colleagues, Medical University of South Carolina Functional Neuroimaging Division, Charleston.)

high-frequency noise artifact that can cause short-term changes in hearing threshold. This is avoided when subjects and investigators wear ear-plugs.¹³¹

The most critical immediate safety concern is that rTMS has resulted in seizures. The number of people who have received TMS or rTMS is unknown, but is likely to be several thousand worldwide. To date, seizures during rTMS are known to have occurred in 7 individuals, including 6 normal volunteers.¹³²⁻¹³⁴ The TMS-induced seizures were self-limiting, and did not seem to have permanent sequelae. The risk of seizure induction is related to the parameters of stimulation, and no seizures have been reported with single-pulse TMS or rTMS delivered at a slow frequency (≤ 1 Hz). There is a growing understanding of the rTMS parameter combinations (magnetic intensity, pulse frequency, train duration, and intertrain interval) that result in spread of excitation, heralding impending seizure.^{10,133} Even if thera-

peutic benefits are convincingly shown, the seizure risk may limit the widespread and loosely supervised use of rTMS. In part for this reason, the therapeutic potential of slow-frequency (≤ 1 Hz) deserves particular attention.

With one exception,^{135,136} examination results of neuropathological specimens in animals exposed to high-intensity rTMS have been normal.¹³⁷⁻¹⁴² The exceptional study found that rTMS resulted in microvacuolar lesions in the neuropil of cortical layers III and IV in rats. This effect was likely artifactual, resulting from mechanical injury due to stimulation-induced head movement. Gates et al¹⁴³ performed histological examinations of the resected temporal lobes of 2 patients with epilepsy who preoperatively received approximately 2000 stimulations over this tissue.¹⁴³ Lesions attributable to TMS were not found. Magnetic resonance imaging scans done before and after 2 weeks of rTMS in 30 depressed patients did not show change.¹⁴⁴

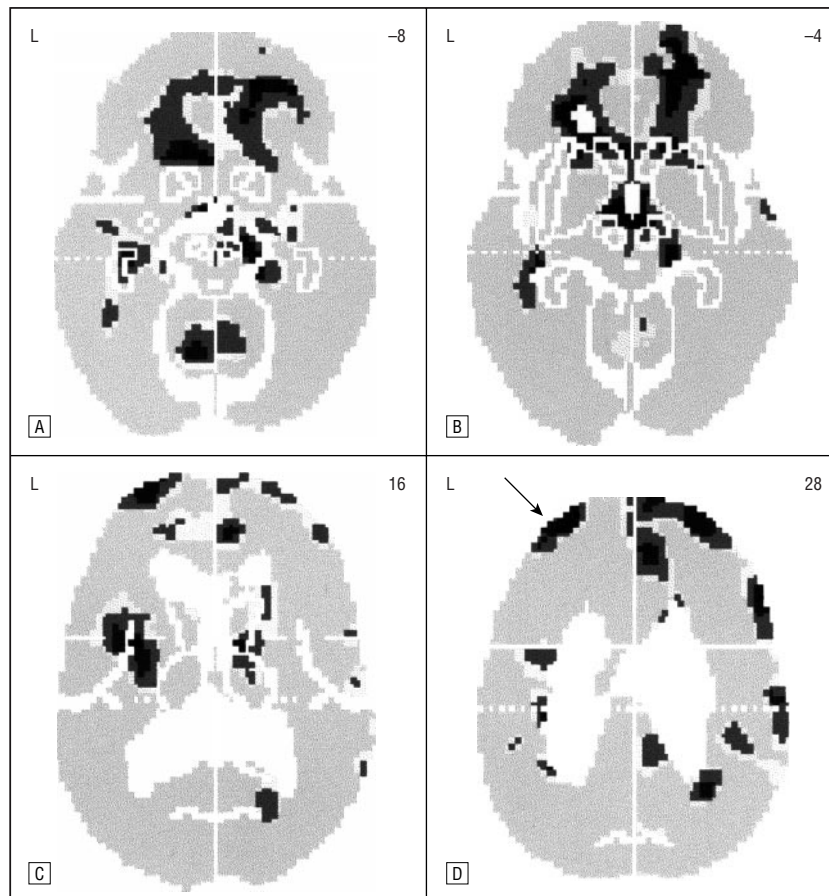


Figure 3. Combining transcranial magnetic stimulation (TMS) with functional imaging reveals TMS neurophysiological effects. Four transverse positron emission tomography images from Kimbrell *et al.*¹²² The nose is at the top of the image, and the right image side is the left side of the brain. These are statistical difference images from 8 adults who had TMS applied at 1 Hz over the left prefrontal cortex (arrow, D) during one scan, and then sham during another. Prefrontal TMS at 1 Hz reduced regional brain activity (blue) locally and in remote areas such as the insula (C) and orbitofrontal cortex (A and B). Although TMS with current technology only directly effects superficial cortex, remote transsynaptic effects also occur.

Both TMS and rTMS can disrupt cognition during the period of stimulation. However, the safety concerns are about alterations in cognitive function beyond the period of stimulation. The limited investigation of short-term neuropsychological effects of TMS has not demonstrated significant changes.³⁹ Little information is available about long-term effects. The technique has been in use for more than a decade without reports of long-term adverse consequences. The rate of cancer is not increased in individuals with prolonged exposure to high-intensity magnetic fields, such as MRI technicians.¹⁴⁵ However, TMS involves extremely brief, focal exposure to high-intensity magnetic fields and thus safety information from MRI technicians, or even people who live near power lines (lengthy exposure to low-

intensity magnetic fields) may not be germane.¹⁴⁶

New pharmacological agents undergo extensive examination of safety in animals and normal volunteers before testing efficacy in clinical trials.¹⁴⁷ To some extent, this scenario has been reversed with rTMS. Controlled trials across a variety of neuropsychiatric conditions are underway, yet safety information is limited. Reassuringly, single-pulse and other TMS measures of cortical excitability are believed to be devoid of significant safety concerns. However, rTMS has shown potential to ameliorate neuropsychiatric symptoms. The potential for adverse cognitive effects must be considered precisely because it is hypothesized that rTMS is a sufficiently powerful modulator of regional functional activity to have therapeutic properties. More com-

prehensive neuropsychological evaluations of the short- and long-term effects of rTMS are needed.

At present, seizure elicitation is the major safety issue linked to rTMS. To avoid seizures, the magnetic intensity delivered with rTMS is adjusted for each individual relative to their motor threshold.^{10,133} This dose-adjustment method rests on the unproven assumption that the seizure risk of rTMS over diverse brain areas is predicted by the threshold for a single TMS pulse to depolarize pyramidal neurons in the motor strip. More needs to be learned about the contribution of rTMS parameters to seizure induction, and validated methods should be established to minimize seizure risk. Much of this work could be conducted in animals. Alternatively, ECT presents the one situation in humans in which seizures are provoked for therapeutic purposes. A reliable method of seizure induction with TMS may have important advantages over traditional ECT by offering better control over the intensity and spatial distribution of current density in the brain.¹⁴⁸ Developing a TMS form of convulsive therapy is largely an issue of technological advances in stimulator output and coil design. Such a development may also foster better understanding of the safety of non-convulsive uses of rTMS.

CONCLUSIONS

During the next several years, it will become clearer whether rTMS has a role in the treatment of psychiatric disorders. To date, trials in depression have focused on demonstrating antidepressant properties and have not demonstrated clinical utility. We need to know a good deal more about the patients who benefit from rTMS, the optimal form of treatment delivery, the magnitude and persistence of therapeutic effects, the capability of sustaining improvement with rTMS or other modalities, and the risks of treatment. It is still too early to know whether we are at the threshold of a new era in physical treatments and noninvasive regional brain modulation. Regardless of its potential therapeutic role, the capacity of rTMS to non-

invasively and focally alter functional brain activity should lead to important advances in our understanding of brain-behavior relationships and the pathophysiology of neuropsychiatric disorders.

Accepted for publication December 16, 1998.

This work was supported in part by grants from the National Alliance for Research in Schizophrenia and Depression (Drs George, Lisanby, and Sackeim), the Ted and Vada Stanley Foundation (Drs George and Sackeim), grant MH35636 from the National Institute of Mental Health, Rockville, Md (Dr Sackeim), and research collaborations with Picker International, Cleveland, Ohio, Dantec (Medtronic), Copenhagen, Denmark (Dr George), and the Magstim Co Ltd, Sheffield, England (Drs Lisanby and Sackeim).

We thank Ziad Nahas, MD, for designing Figure 2.

Reprints: Mark S. George, MD, Radiology Department, Medical University of South Carolina, 171 Ashley Ave, Charleston, SC 29425 (e-mail: georgem@musc.edu).

REFERENCES

1. Penfield W, Jasper H. *Epilepsy and the Functional Anatomy of the Human Brain*. Boston, Mass: Little, Brown & Co; 1954.
2. Saypol JM, Roth BJ, Cohen LG, Hallett M. A theoretical comparison of electric and magnetic stimulation of the brain. *Ann Biomed Eng*. 1991; 19:317-328.
3. Fink M. *Convulsive Therapy: Theory and Practice*. New York, NY: Raven Press; 1979.
4. Pridmore S, Filho JAF, Nahas Z, Liberatos C, George MS. Motor threshold in transcranial magnetic stimulation: a comparison of a neurophysiological and a visualization of movement method. *J ECT*. 1998;14:25-27.
5. Wassermann EM, McShane LM, Hallett M, Cohen LG. Noninvasive mapping of muscle representations in human motor cortex. *Electroencephalogr Clin Neurol*. 1992;85:1-8.
6. Bohning DE, Pecheny AP, Epstein CM, Vincent DJ, Dannels WR, George MS. Mapping transcranial magnetic stimulation (TMS) fields in vivo with MRI. *Neuroreport*. 1997;8:2535-2538.
7. Roth BJ, Cohen LG, Hallett M. *The Electric Field Induced During Magnetic Stimulation, Magnetic Motor Stimulation: Basic Principles and Clinical Experience* [EEG Suppl 43]. Lecy WJ, Cracco RQ, Barker AT, Rothwell J, eds. Amsterdam, the Netherlands: Elsevier Science Publishers; 1991:268-278.
8. Cohen LG, Roth BJ, Nilsson J, Dang N, Panizza M, Bandinelli S, Fraiua W, Hallett M. Effects of coil design on delivery of focal magnetic stimulation: technical considerations. *Electroencephalogr Clin Neurol*. 1990;75:350-357.
9. Amassian VE, Cracco RQ, Maccabee PJ, Cracco JB, Rudell A, Eberle L. Suppression of visual perception by magnetic coil stimulation of human

occipital cortex. *Electroencephalogr Clin Neurol*. 1989;74:458-462.

10. Wassermann EM. Risk and safety of repetitive transcranial magnetic stimulation: report and suggested guidelines from the International Workshop in the Safety of Repetitive Transcranial Magnetic Stimulation, June 5-7, 1996. *Electroencephalogr Clin Neurophysiol*. 1998;108:1-16.
11. Penfield W, Perot P. The brain's record of auditory and visual experience: a final summary and discussion. *Brain*. 1963;86:595-696.
12. Kujirai T. Corticocortical inhibition in human motor cortex. *J Physiol (Lond)*. 1993;471:501-519.
13. Hoflich G, Kasper S, Hufnagel A, Ruhrmann S, Moller HJ. Application of transcranial magnetic stimulation in treatment of drug-resistant major depression: a report of two cases. *Hum Psychopharmacol*. 1993;8:361-365.
14. Grisar N, Yaroslavsky U, Abarbanel J, Lamberg T, Belmaker RH. Transcranial magnetic stimulation in depression and schizophrenia. *Eur Neuropsychopharmacol*. 1994;4:287-288.
15. Kolbinger HM, Hofflich G, Hufnagel A, Moller H-J, Kasper S. Transcranial magnetic stimulation (TMS) in the treatment of major depression: a pilot study. *Hum Psychopharmacol*. 1995;10:305-310.
16. George MS, Ketter TA, Post RM. Prefrontal cortex dysfunction in clinical depression. *Depression*. 1994;2:59-72.
17. George MS, Ketter TA, Post RM. What functional imaging studies have revealed about the brain basis of mood and emotion. In: Panksepp J, ed. *Advances in Biological Psychiatry*. Greenwich, Conn: JAI Press; 1996:63-113.
18. Nobler MS, Sackeim HA, Prohovnik I, Moeller JR, Mukherjee S, Schnur DB, Prudic J, Devanand DP. Regional cerebral blood flow in mood disorders, III: treatment and clinical response. *Arch Gen Psychiatry*. 1994;51:884-897.
19. George MS, Wassermann EM. Rapid-rate transcranial magnetic stimulation (rTMS) and ECT. *Convulsive Ther*. 1994;10:251-253.
20. George MS. Why would you ever want to? toward understanding the antidepressant effect of rTMS. *Hum Psychopharmacol*. 1998;13:307-313.
21. George MS, Wassermann EM, Williams WA, Callahan A, Ketter TA, Basser P, Hallett M, Post RM. Daily repetitive transcranial magnetic stimulation (rTMS) improves mood in depression. *Neuroreport*. 1995;6:1853-1856.
22. Figiel GS, Epstein C, McDonald WM, Amazon-Leece J, Figiel L, Saldivia A, Glover S. The use of rapid rate transcranial magnetic stimulation (rTMS) in refractory depressed patients. *J Neuropsychiatry Clin Neurosci*. 1998;10:20-25.
23. Conca A, Koppi S, Konig P, Swoboda W, Krecke N. Transcranial magnetic stimulation: a novel antidepressive strategy? *Neuropsychobiology*. 1996;34:204-207.
24. Pascual-Leone A, Rubio B, Pallardo F, Catala MD. Beneficial effect of rapid-rate transcranial magnetic stimulation of the left dorsolateral prefrontal cortex in drug-resistant depression. *Lancet*. 1996;348:233-237.
25. Segman RH, Shapira B, Gorfine M, Lerer B. Onset and time course of antidepressant action: psychopharmacological implications of a controlled trial of electroconvulsive therapy. *Psychopharmacology*. 1995;119:440-448.
26. Nobler MS, Sackeim HA, Moeller JR, Prudic J, Petkova E, Watermaux C. Quantifying the speed of symptomatic improvement with electroconvulsive therapy: comparison of alternative statistical methods. *Convulsive Ther*. 1997;13:208-221.
27. Padberg F, Haag C, Zwanzger P, Thoma H, Kathmann N, Stubner S, Hampel H, Moller HJ. Rapid and slow transcranial magnetic stimulation are equally effective in medication-resistant depression: a placebo-controlled study [abstract]. *CINP Abstracts*. 1998;21:103.
28. Loo C, Mitchell P, Sachdev P, McDermont B, Gandevia S. rTMS: A sham-controlled trial in medication-resistant depression [abstract]. *Biol Psychiatry*. 1998;43:95.
29. Grunhaus L, Dannon P, Schrieber S. Effects of

transcranial magnetic stimulation on severe depression: similarities with ECT [abstract]. *Biol Psychiatry*. 1998;43:76.

30. Pridmore S. Substitution of rapid transcranial magnetic stimulation treatments for electroconvulsive therapy treatments in a course of electroconvulsive therapy. *Prog Neuropsychopharmacol Biol Psychiatry*. In press.
31. George MS, Wassermann EM, Williams WE, Kimbrell TA, Little JT, Hallett M, Post RM. Mood improvements following daily left prefrontal repetitive transcranial magnetic stimulation in patients with depression: a placebo-controlled crossover trial. *Am J Psychiatry*. 1997;154:1752-1756.
32. Klein E, Kreinin I, Chistyakov A, Feinsod M. Therapeutic efficacy of prefrontal repetitive transcranial magnetic stimulation in major depression: a double-blind controlled study [abstract]. Presented at: American College of Neuropsychopharmacology 36th annual meeting; December 10, 1997; Waikoloa, Hawaii.
33. Klein E, Kreinin I, Chistyakov A, Koren D, Mecz L, Marmor S, Ben-shachar D, Feinsod M. Therapeutic efficacy of right prefrontal slow repetitive transcranial magnetic stimulation in major depression: a double-blind controlled study. *Arch Gen Psychiatry*. 1999;56:315-320.
34. Nahas Z, Speer AM, Molloy M, Arana GW, Risch SC, George MS. Preliminary results concerning the roles of frequency and intensity in the antidepressant effect of daily left prefrontal rTMS [abstract]. *Biol Psychiatry*. 1998;43:94.
35. George MS, Speer AM, Molloy M, Nahas Z, Tenback CC, Risch SC, Arana GW, Ballenger JC, Post RM. Low-frequency daily left prefrontal rTMS improves mood in bipolar depression: a placebo-controlled case report. *Hum Psychopharmacol*. 1998;13:271-275.
36. Belmaker RH, Grisar N. Does TMS have bipolar efficacy in both depression and mania [abstract]? *Biol Psychiatry*. 1998;43:755.
37. Grisar N, Chudakov B, Yaroslavsky Y, Belmaker RH. TMS in Mania: a controlled study. *Am J Psychiatry*. 1998;155:1608-1610.
38. Stassen HH, Delini-Stula A, Angst J. Time course of improvement under antidepressant treatment: a survival analytic approach. *Eur Neuropsychopharmacol*. 1993;3:127-135.
39. Stassen HH, Angst J, Delini-Stula A. Severity at baseline and onset of improvement in depression: meta-analysis of imipramine and moclobemide versus placebo. *Eur Psychiatry*. 1994; 9:129-136.
40. Laska EM, Klein DF, Lavori PW, Levine J, Robinson DS. Design issues for the clinical evaluation of psychotropic drugs. In: Prien RF, Robinson DF, eds. *Clinical Evaluation of Psychotropic Drugs*. New York, NY: Raven Press; 1994:29-67.
41. Feinsod M, Kreinin B, Chistyakov A, Klein E. Preliminary evidence for a beneficial effect of low-frequency, repetitive transcranial magnetic stimulation in patients with major depression and schizophrenia. *Depress Anxiety*. 1998;7:65-68.
42. Lisanby SH, Luber B, Schroeder C, Osman M, Finck D, Jalinos R, Amassian VE, Arezzo J, Sackeim HA. Intracerebral measurement of rTMS and ECS induced voltage in vivo. *Biol Psychiatry*. 1998;43:100.
43. Sackeim HA, Decina P, Portnoy S, Neeley P, Malitz S. Studies of dosage, seizure threshold, and seizure duration in ECT. *Biol Psychiatry*. 1987;22:249-268.
44. Sackeim HA, Prudic J, Devanand DP, Kiersky JE, Fitzsimmons L, Moody BJ, McElhiney MC, Coleman EA, Settembrino JM. Effects of stimulus intensity and electrode placement on the efficacy and cognitive effects of electroconvulsive therapy. *N Engl J Med*. 1993;328:839-846.
45. Greenberg BD, George MS, Dearing J, Benjamin J, Schlaepfer T, Altemus M, Wassermann EM, Hallett M, Murphy DL. Effect of prefrontal repetitive transcranial magnetic stimulation (rTMS) in obsessive-compulsive disorder: a preliminary study. *Am J Psychiatry*. 1997;154:867-869.

46. Cora-Locatelli G, Greenberg BD, Harmon A, Martin J, Ziemann U, Wassermann E, Leong YM, Murphy DL. Cortical excitability and augmentation strategies in OCD [abstract]. *Biol Psychiatry*. 1998;43:77.
47. Greenberg BD, Rauch SL. Transcranial magnetic stimulation in anxiety disorders. In: George MS, Belmaker RH, eds. *Transcranial Magnetic Stimulation in Neuropsychiatry*. Washington, DC: American Psychiatric Press. In press.
48. Ziemann U, Paulus W, Rothenberger A. Decreased motor inhibition in Tourette's disorder: evidence from transcranial magnetic stimulation. *Am J Psychiatry*. 1997;154:1277-1284.
49. Ingham RJ, Fox PT, Ingham JC, Collins J, Pridgen S. TMS in developmental stuttering and Tourette syndrome. In: George MS, Belmaker RH, eds. *Transcranial Magnetic Stimulation in Neuropsychiatry*. Washington, DC: American Psychiatric Press. In press.
50. McCann UD, Kimbrell TA, Morgan CM, Anderson T, Geraci M, Benson BE, Wassermann EM, Willis MW, Post RM. Repetitive transcranial magnetic stimulation for posttraumatic stress disorder [letter]. *Arch Gen Psychiatry*. 1998;55:276-279.
51. Grisaru N, Amir M, Cohen H, Kaplan Z. Effect of transcranial magnetic stimulation in posttraumatic stress disorder: a preliminary study. *Biol Psychiatry*. 1998;44:52-55.
52. Puri BK, Davey NJ, Ellaway PH, Lewis SW. An investigation of motor function in schizophrenia using transcranial magnetic stimulation of the motor cortex. *Br J Psychiatry*. 1996;169:690-695.
53. Hoffman R, Boutros N, Berman R, Krystal J, Charney D. Transcranial magnetic stimulation and hallucinated voices [abstract]. *Biol Psychiatry*. 1998;43:93.
54. Nahas Z, McConnell K, Collins S, Molloy M, Oliver NC, Risch SC, Christie S, Arana GW, George MS. Could left prefrontal rTMS modify negative symptoms and attention in schizophrenia [abstract]? *Biol Psychiatry*. In press.
55. Pascual-Leone A, Valls-Sole J, Brasil-Neto JP, Cohen LG, Hallett M. Akinesia in Parkinson's disease, I: shortening of simple reaction times with focal, single-pulse transcranial magnetic stimulation. *Neurology*. 1994;44:884-891.
56. Pascual-Leone A, Valls-Sole J, Brasil-Neto JP, Cammarota A, Grafman J, Hallett M. Akinesia in Parkinson's Disease, II: effects of subthreshold repetitive transcranial motor cortex stimulation. *Neurology*. 1994;44:892-898.
57. Ghabra MB, Hallett M, Wassermann EM. Repetitive transcranial magnetic stimulation does not improve performance on the grooved pegboard task in Parkinson's disease [abstract]. *Mov Disord*. In press.
58. Ghabra MB, Hallett M, Wassermann EM. Simultaneous repetitive transcranial magnetic stimulation does not speed fine movement in PD. *Neurology*. In press.
59. Siebner HR, Tormos JM, Ceballos-Baumann AO, Aher C, Catala MD, Conrad B, Pascual-Leone A. Slow repetitive transcranial magnetic stimulation of motor cortex in patients with writer's cramp. *Ann Neurol*. In press.
60. Reutens DC, Puce A, Berkovic SF. Cortical hyperexcitability in progressive myoclonus epilepsy: a study with transcranial magnetic stimulation. *Neurology*. 1993;43:186-192.
61. Epstein CM, Lah JJ, Meador K, Weissman JD, Gaitan LE, Dihenia B. Optimum stimulus parameters for lateralized suppression of speech with magnetic brain stimulation. *Neurology*. 1996;47:1590-1593.
62. Wedegaertner F, Garvey M, Cohen LG, Hallett M, Wassermann EM. Low-frequency repetitive transcranial magnetic stimulation can reduce action myoclonus [abstract]. *Neurology*. 1997;48:A119.
63. Brasil-Neto JP, McShane LM, Fuhr P, Hallett M, Cohen LG. Topographic mapping of the human motor cortex with magnetic stimulation: factors affecting accuracy and reproducibility. *Electroencephalogr Clin Neurol*. 1992;85:9-16.
64. Cohen LG, Bandinelli S, Topka HR, Fuhr P, Roth BJ, Hallett M. Topographic maps of human motor cortex in normal and pathological conditions: mirror movements, amputations and spinal cord injuries. *Electroencephalogr Clin Neurophysiol*. 1991;43:36-50.
65. Levy WJ, Amassian VE, Schmid UD, Jungreis C. Mapping of motor cortex gyral sites non-invasively by transcranial magnetic stimulation in normal subjects and patients. *Electroencephalogr Clin Neurophysiol*. 1991;43:51-75.
66. Pascual-Leone A, Torres F. Plasticity of the sensorimotor cortex representation of the reading finger in Braille readers. *Brain*. 1993;116:39-52.
67. Ziemann U, Corwell B, Cohen LG. Modulation of plasticity in human motor cortex after forearm ischemic nerve block. *J Neurosci*. 1998;18:1115-1123.
68. Amassian VE, Cracco RQ, Maccabee PJ, Cracco JB, Henry K. Some positive effects of transcranial magnetic stimulation. *Adv Neurosci*. 1995;67:79-106.
69. Pascual-Leone A, Gomez-Tortosa E, Grafman J, Alway D, Nichelli P, Hallett M. Induction of visual extinction by rapid-rate transcranial magnetic stimulation (rTMS) of parietal lobe. *Neurology*. 1994;44:494-498.
70. Takayama Y, Sugishita M. Astereopsis induced by repetitive magnetic stimulation of occipital cortex. *J Neurol*. 1994;241:522-525.
71. Beckers G, Homberg V. Cerebral vision motion blindness: transitory akinetopsia induced by transcranial magnetic stimulation of human area V5. *Proc R Soc Lond*. 1992;249:173-178.
72. Beckers G, Zeki S. The consequences of inactivating areas V1 and V5 on visual motion perception. *Brain*. 1995;118:49-60.
73. Hotson J, Braun D, Herzberg W, Boman D. Transcranial magnetic stimulation of extrastriate cortex degrades human motion direction discrimination. *Vis Res*. 1994;34:2115-2123.
74. Amassian VE. Unmasking human visual perception with the magnetic coil and its relationship to hemispheric asymmetry. *Brain Res*. 1993;605:312-316.
75. Amassian VE, Maccabee PJ, Cracco RQ, Cracco JB, Rudell AP, Eberle L. Measurement of information processing delays in human visual cortex with repetitive magnetic coil stimulation. *Brain Res*. 1993;605:317-321.
76. Pascual-Leone A, Gates JR, Dhuna A. Induction of speech arrest and counting errors with rapid-rate transcranial magnetic stimulation. *Neurology*. 1991;41:697-702.
77. Jennum P, Friberg L, Fuglsang-Fredericksen A, Dam M. Speech localization using repetitive transcranial magnetic stimulation. *Neurology*. 1994;44:269-273.
78. Ferbert A, Mussmann N, Menne A, Buchner H, Hartje W. Short-term memory performance with magnetic stimulation of the motor cortex. *Eur Arch Psychiatry Clin Neurosci*. 1991;241:135-138.
79. Hufnagel A, Elger CE, Klingmuller D, Zierz S, Kramer R. Activation of epileptic foci by transcranial magnetic stimulation: effects on secretion of prolactin and luteinizing hormone. *J Neurol*. 1995;237:242-246.
80. Grafman J, Pascual-Leone A, Alway D, Nichelli P, Gomez-Tortosa E, Hallett M. Induction of a recall deficit by rapid-rate transcranial magnetic stimulation. *Neuroreport*. 1994;5:1157-1160.
81. Pascual-Leone A, Hallett M. Induction of errors in a delayed response task by repetitive transcranial magnetic stimulation of the dorsolateral prefrontal cortex. *Neuroreport*. 1994;5:2517-2520.
82. George MS, Wassermann EM, Williams W, Steppe J, Pascual-Leone A, Basser P, Hallett M, Post RM. Changes in mood and hormone levels after rapid-rate transcranial magnetic stimulation of the prefrontal cortex. *J Neuropsychiatry Clin Neurosci*. 1996;8:172-180.
83. Pascual-Leone A, Catala MD, Pascual AP. Lateralized effect of rapid-rate transcranial magnetic stimulation of the prefrontal cortex on mood. *Neurology*. 1996;46:499-502.
84. Martin JD, George MS, Greenberg BD, Wassermann EM, Schlaepfer TE, Murphy DL, Hallett M, Post RM. Mood effects of prefrontal repetitive high-frequency TMS in healthy volunteers. *Int J Neuropsychiatry Med*. 1997;2:53-68.
85. George MS, Ketter TA, Parekh PI, Gill DS, Marangell L, Pazzaglia PJ, Herscovitch P, Post RM. Depressed subjects have abnormal right hemisphere activation during facial emotion recognition. *CNS Spectrums*. 1997;2:45-55.
86. George MS, Parekh PI, Rosinsky N, Ketter TA, Kimbrell TA, Heilman K, Herscovitch P, Post RM. Understanding emotional prosody activates right hemisphere regions. *Arch Neurol*. 1996;53:665-670.
87. Sackeim HA, Gur RC, Saucy MC. Emotions are expressed more intensely on the left side of the face. *Science*. 1978;202:434-436.
88. Homberg V, Stephan KM, Netz J. Transcranial stimulation of motor cortex in upper motor neurone syndrome: its relation to motor deficit. *Electroencephalogr Clin Neurophysiol*. 1991;81:377-388.
89. Hufnagel A, Elger CE, Durven HF, Baker DK, Entzian W. Activation of the epileptic focus by transcranial magnetic stimulation of the human brain. *Ann Neurol*. 1990;27:49-60.
90. Reutens DC, Berkovic SF, MacDonell RAL, Bladin PF. Magnetic stimulation of the brain in generalized epilepsy: reversal of cortical hyperexcitability by anticonvulsants. *Ann Neurol*. 1993;34:351-355.
91. Abarbanel JM, Lemberg T, Yaroslavski U, Grisaru N, Belmaker RH. Electrophysiological responses to transcranial magnetic stimulation in depression and schizophrenia. *Biol Psychiatry*. 1996;40:148-150.
92. Samii A, Ikoma K, Mercuri B, George MS, Hallett M, Wassermann EM. Decreased post-exercise facilitation of motor evoked potentials in depressed patients [abstract]. *Neurology*. 1996;47:1410.
93. Hess CW, Mills KR, Murray NMF, Schriefer TN. Magnetic brain stimulation: central motor conduction studies in multiple sclerosis. *Ann Neurol*. 1987;22:744-752.
94. Martinez AC, Anciones B. Central motor pathway conduction after magnetic stimulation of the brain in Cockayne's syndrome. *Acta Neurol Scand*. 1991;84:291-294.
95. Salerno A, Georgesco M. Interhemispheric facilitation and inhibition studies in man with double magnetic stimulation. *Electroencephalogr Clin Neurophysiol*. 1996;101:395-403.
96. Fong JKY. Motor cortex excitability in focal and generalized epilepsy. *J Physiol (Lond)*. 1993;459-468.
97. Pascual-Leone A, Valls-Sole J, Wassermann EM, Brasil-Neto JP, Hallett M. Responses to rapid-rate transcranial magnetic stimulation of the human motor cortex. *Brain*. 1994;117:847-858.
98. Wassermann EM, Wedegaertner FR, Ziemann U, George MS, Chen R. Crossed reduction of motor cortex excitability by 1 Hz transcranial magnetic stimulation. *Neurosci Lett*. 1998;250:141-144.
99. Chen R, Classen J, Gerloff C, Celnik P, Wassermann EM, Hallett M, Cohen LG. Depression of motor cortex excitability by low-frequency transcranial magnetic stimulation. *Neurology*. 1997;48:1398-1403.
100. Tergau F, Tormos JM, Paulus W. Modulation of motor cortical excitability by repetitive transcranial magnetic stimulation on cortico-spinal and cortico-cortical excitability [abstract]. *Neurology*. 1997;48:A107.
101. Wang H, Wang X, Scheich H. LTD and LTP induced by transcranial magnetic stimulation in auditory cortex. *Neuroreport*. 1996;7:521-525.
102. Lisanby SH, Luber B, Finck D, Osman M, Dichter G, Fitzsimmons L, Sackeim HA. Primate models of transcranial magnetic stimulation [abstract]. *Biol Psychiatry*. 1998;41:76.
103. Amassian VE, Quirk GJ, Stewart M. A comparison of corticospinal activation by magnetic coil and electrical stimulation of monkey motor cortex. *Electroencephalogr Clin Neurophysiol*. 1990;77:390-401.

104. Olivier E, Edgley SA, Armand J, Lemon RN. An electrophysiological study of the postnatal development of the corticospinal system in the macaque monkey. *J Neurosci*. 1997;17:267-276.
105. Flament D, Hall EJ, Lemon RN. The development of cortico-motoneuronal projections investigated using magnetic brain stimulation in the infant macaque. *J Physiol (Lond)*. 1992;447:755-768.
106. Edgley SA, Eyre JA, Lemon RN, Miller S. Excitation of the corticospinal tract by electromagnetic and electrical stimulation of the scalp in the macaque monkey. *J Physiol (Lond)*. 1990;425:301-320.
107. Lemon RN, Johansson RS, Wrestrling G. Modulation of corticospinal influence over hand muscles during gripping tasks in man and monkey. *Can J Physiol Pharmacol*. 1996;74:547-558.
108. Baker SN, Olivier E, Lemon RN. Task-related variation in corticospinal output evoked by transcranial magnetic stimulation in the macaque monkey. *J Physiol*. 1995;488:795-801.
109. Ghaly RF, Stone JL, Aldrete A, Levy W. Effects of incremental ketamine hydrochloride doses on motor evoked potentials (MEPs) following transcranial magnetic stimulation: a primate study. *J Neurosurg Anesthesiol*. 1990;2:79-85.
110. Stone JL, Ghaly RF, Levy WJ, Kartha R, Krinsky L, Roccaforte P. A comparative analysis of enflurane anesthesia on primate motor and somatosensory evoked potentials. *Electroencephalogr Clin Neurophysiol*. 1992;84:180-197.
111. Baker SN, Olivier E, Lemon RN. Recording an identified pyramidal volley evoked by transcranial magnetic stimulation in a conscious macaque monkey. *Exp Brain Res*. 1995;99:529-532.
112. Fleischmann A, Steppel J, Leon A, Belmaker RH. The effect of transcranial magnetic stimulation compared with electroconvulsive shock on rat apomorphine-induced stereotypy. *Eur Neuro-psychopharmacol*. 1994;4:449-450.
113. Fleischmann A, Sternheim A, Etgen AM, Li C, Grisaru N, Belmaker RH. Transcranial magnetic stimulation downregulates beta-adrenoreceptors in rat cortex. *J Neural Transm*. 1996;103:1361-1366.
114. Ben-Sachar D, Belmaker RH, Grisaru N, Klein E. Transcranial magnetic stimulation induces alterations in brain monoamines. *J Neural Transm*. 1997;104:191-197.
115. Fujiki M, Steward O. High frequency transcranial magnetic stimulation mimics the effects of ECS in upregulating astroglial gene expression in the murine CNS. *Mol Brain Res*. 1997;44:301-308.
116. Jennum P, Klitgaard H. Effect of acute and chronic stimulations on pentylentetrazole-induced clonic seizures. *Epilepsy Res*. 1996;23:115-122.
117. Wassermann EM, Wang B, Toro C. Projecting transcranial magnetic stimulation (TMS) maps into brain MRI [abstracts]. *Soc Neurosci Abstracts*. 1992;18.
118. Roberts DR, Vincent DJ, Speer AM, Bohning DE, Cure J, Young J, George MS. Multi-modality mapping of motor cortex: comparing echoplanar BOLD fMRI and transcranial magnetic stimulation. *J Neural Transm*. 1997;104:833-843.
119. Paus T, Jech R, Thompson CJ, Comeau R, Peters T, Evans AC. Transcranial magnetic stimulation during positron emission tomography: a new method for studying connectivity of the human cerebral cortex. *J Neurosci*. 1997;17:3178-3184.
120. Paus T, Jech R, Thompson CJ, Comeau R, Peters T, Evans AC. Dose-dependent reduction of cerebral blood flow during rapid-rate transcranial magnetic stimulation of the human sensorimotor cortex. *J Neurophysiol*. 1997;79:1102-1107.
121. Wassermann EM, Kimbrell TA, George MS, Danielson AL, Herscovitch P, Hallett M, Post RM. Local and distant changes in cerebral glucose metabolism during repetitive transcranial magnetic stimulation (rTMS) [abstract]. *Neurology*. 1997;48:A107.
122. Kimbrell TA, George MS, Danielson AL, Dunn RT, Benson BE, Little JT, Herscovitch P, Hallett M, Post RM, Wassermann EM. Changes in cerebral metabolism during transcranial magnetic stimulation [abstract]. *Biol Psychiatry*. 1997;41:108S.
123. Stallings LE, Speer AM, Spicer KM, Cheng KT, George MS. Combining SPECT and repetitive transcranial magnetic stimulation (rTMS): left prefrontal stimulation decreases relative perfusion locally in a dose-dependent manner [abstract]. *Neuroimage*. 1997;5:S521.
124. Nahas Z, Stallings LE, Speer AM, Teneback CC, Vincent DJ, Bohning DE, Spicer KM, Cheng KT, Molloy M, Risch SC, George MS. Perfusion SPECT studies of rTMS on blood flow in health and depression [abstract]. *Biol Psychiatry*. 1998;43:19S.
125. George MS, Stallings LE, Speer AM, Spicer KM, Vincent DJ, Bohning DE, Cheng KT, Molloy M, Risch SC. A pilot study using perfusion SPECT to image regional brain activity during prefrontal repetitive transcranial magnetic stimulation (rTMS) [abstract]. *Hum Psychopharmacol*. In press.
126. Fox P, Ingham R, George MS, Mayberg HS, Ingham J, Roby J, Martin C, Jerabek P. Imaging human intracerebral connectivity by PET during TMS. *Neuroreport*. 1997;8:2787-2791.
127. Bohning DE, Shastri A, Nahas Z, Lorberbaum JP, Anderson SW, Dannels W, Vincent DJ, George MS. Echoplanar BOLD fMRI of brain activation induced by concurrent transcranial magnetic stimulation (TMS). *Invest Radiol*. 1998;33:336-340.
128. Shastri A, George MS, Bohning DE. Performance of a system for interleaving transcranial magnetic stimulation with steady-state magnetic resonance imaging. *Electroencephalogr Clin Neurophysiol*. In press.
129. Bohning DE, Shastri A, McConnell K, Nahas Z, Lorberbaum J, Roberts D, Teneback C, Vincent DJ, George MS. A Combined TMS/fMRI study of intensity-dependent TMS over motor cortex. *Biol Psychiatry*. In press.
130. George MS, Bohning DE, Shastri A, Nahas Z, Lorberbaum JP, Speer AM, Vincent DJ. Using functional imaging to understand the neurobiological effects of TMS [abstract]. Presented at: Internationale Neuropsychopharmacologie annual meeting; July 14, 1998; Glasgow, Scotland.
131. Pascual-Leone A, Cohen LG, Shottland LI, Dang N, Pikus A, Wasserman EM, Brasil-Neto JP, Valls-Sole J, Hallett M. No evidence of hearing loss in humans due to transcranial magnetic stimulation. *Neurology*. 1992;42:647-651.
132. Wassermann EM, Grafman J, Berry C, Hollnagel C, Wild K, Clark K, Hallett M. Use and safety of a new repetitive transcranial magnetic stimulator. *Electroencephalogr Clin Neuro*. 1996;101:412-417.
133. Pascual-Leone A, Houser CM, Reese K, Shottland LI, Grafman J, Sato S, Valls-Sole J, Brasil-Neto JP, Wasserman EM, Cohen LG, Hallett M. Safety of rapid-rate transcranial magnetic stimulation in normal volunteers. *Electroencephalogr Clin Neurophysiol*. 1993;89:120-130.
134. Wassermann EM, Cohen LG, Fittman SS, Chen R, Hallett M. Seizures in healthy people with repeated safe trains of transcranial magnetic stimuli. *Lancet*. 1996;347:825-826.
135. Matsumiya Y, Yamamoto T, Miyauchi S, Yaita M, Kling JW. Effect of pulsed magnetic stimulation of the head, II: neuropathological changes in the rat. *J Clin Neurophysiol*. 1989;6:354.
136. Matsumiya Y, Yamamoto T, Yaita M, Miyauchi S, Kling JW. Physical and physiological specification of magnetic pulse stimuli that produced cortical damage in rats. *J Clin Neurophysiol*. 1992;9:287.
137. Mano Y, Funakawa I, Nakamura T, Ikoma K, Takayanagi T, Matsui K. The safety of magnetic stimulation. In: Wallinga W, Boom HBK, DeVries J, eds. *Electrophysiological Kinesiology*. Amsterdam, the Netherlands: Elsevier Science Publishers; 1998:191-194.
138. Tsubokawa T, Yamamoto T, Nakamura S. Electrophysiological and morphological consequences of repeated magnetic stimulation of the brain and peripheral nerve. Presented at: 1989 International Motor Evoked Potentials Symposium.
139. Kling JW, Yaita M, Yamamoto T, Matsumiya Y. Memory for conditioned taste aversions is diminished by transcranial magnetic stimulation. *Physiol Behav*. 1990;48:713-717.
140. Sgro JA, Stanton PC, Emerson RG, Blair R, Ghatak NR. Repetitive high magnetic field stimulation: the effect upon rat brain. *Electroencephalogr Clin Neurophysiol Suppl*. 1991;43:180-185.
141. Counter SA. Neurobiological effects of extensive transcranial electromagnetic stimulation in an animal model. *Electroencephalogr Clin Neurophysiol*. 1993;89:341-348.
142. Counter SA. Auditory brainstem and cortical responses following extensive transcranial magnetic stimulation. *J Neurol Sci*. 1994;124:163-170.
143. Gates JR, Dhuna A, Pascual-Leone A. Lack of pathologic changes in human temporal lobes after transcranial magnetic stimulation. *Epilepsia*. 1992;33:504-508.
144. Nahas Z, Speer AM, Lorberbaum JP, Molloy M, Liberatos C, Risch SC, George MS. Safety of rTMS: MRI scans before and after 2 weeks of daily left prefrontal rTMS for depression [abstract]. *Biol Psychiatry*. 1998;43:95.
145. Baker KA, DeVos D. Safety considerations with high-field MRI. *Radiol Technol*. 1996;67:251-252.
146. National Research Council. *Possible Health Effects of Exposure to Residential Electric and Magnetic Fields*. Washington, DC: National Academy Press; 1996.
147. Laughren TP, Levine J, Levine JG, Thompson WL. Premarketing safety evaluation of psychotropic drugs. In: Prien RF, Robinson DS. *Clinical Evaluation of Psychotropic Drugs: Principles and Guidelines*. New York, NY: Raven Press; 1994:185-215.
148. Sackeim HA. Magnetic Stimulation Therapy and ECT. *Convulsive Ther*. 1994;10:255-258.